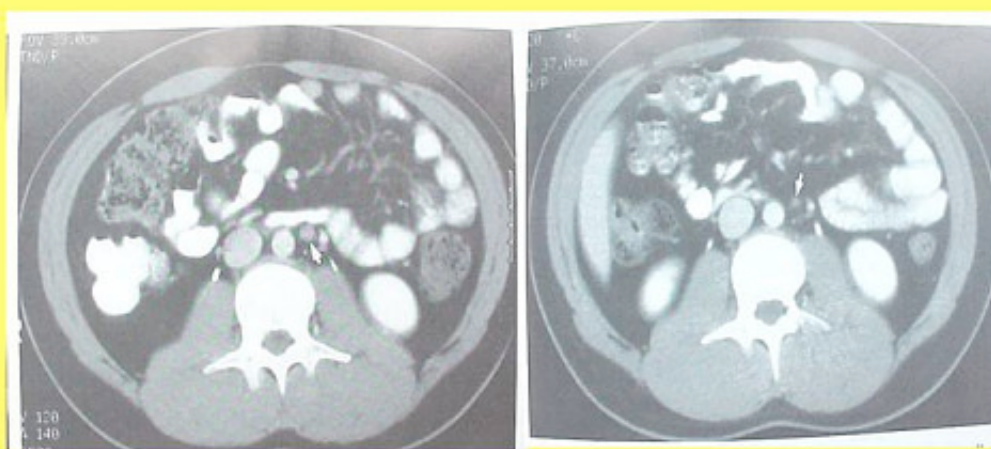


Metastatic Colon Cancer

Case History:

The 59 year old Mrs. A.H. was diagnosed with a metastatic colon cancer. Several enlarged lymph nodes, close to the abdominal aorta, were found with CT-scan suspicious for metastases in February 2002. There was also evidence of liver involvement. Treatment with loco-regional hyperthermia and AVEMAR[®] for several months produced significant reduction of the metastatic lesions.

Reduction of lymphnode metastases under AVEMAR[®] therapy



A.H., 59 years, Feb 2002

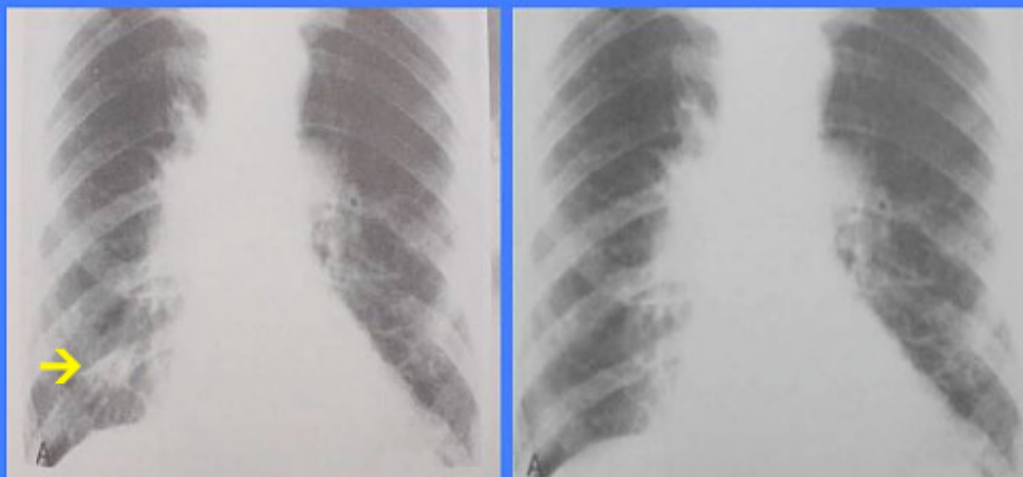A.H., 59 years, Oct 2002

Metastatic Prostate Cancer

Case History:

The 63 year old Mr. K.B. was diagnosed with a metastatic prostate carcinoma. A large lung metastasis caused recurrent cough, and his bone metastases caused considerable pain not well responding to therapy even with strong pain killers. Treatment with ProstaSol (a phytotherapeutic compound with efficacy in prostate cancer) and AVEMAR[®] for about 9 months caused complete resolution of the lung lesion and a marked reduction in bone metastases and cancer related pain.

Reduction of lung metastasis under therapy with ProstaSol and AVEMAR[®]



K.R., 63 years, 20.4.2002

K.R., 63 years, 14.1.2003